

EQUINE TOMOSYNTHESIS

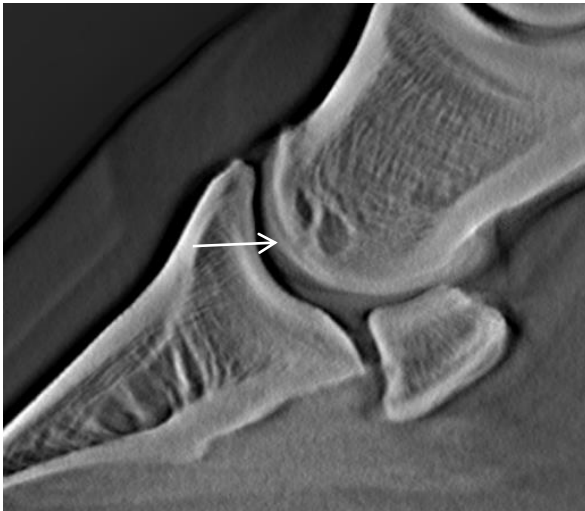
LF Foot (L0020, 10 Sep 2019)

Jumping mare 10 years old. Lameness both front feet on hard ground on small circle. Synovitis of the right front fetlock joint, dynamic flex test positive (degree 3 from 4). Synovitis of the right tarsal joint, dynamic flex test was negative. EqueTom and DR x-ray images was make for comparative evaluation of findings.

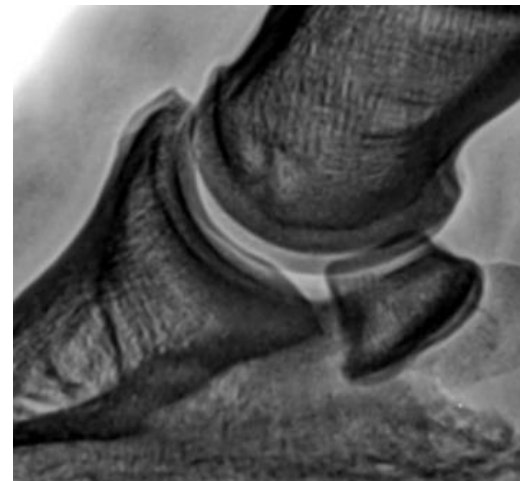
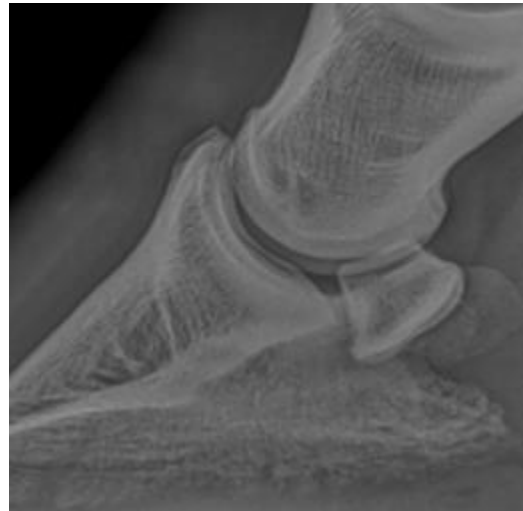
LF Foot

There is a subchondral lucency in the distal aspect of the middle phalanx. The lucent area is irregularly margined and surrounded by sclerotic bone. The lucent area has several septa and on EqueTom images clearly visualized the channel open to the joint cavity.

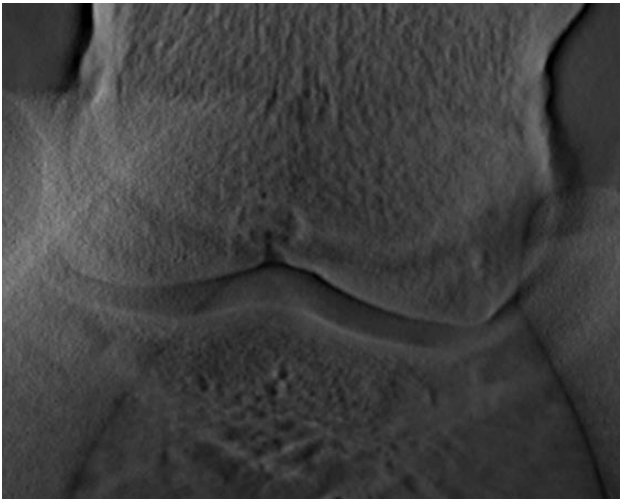
DTS



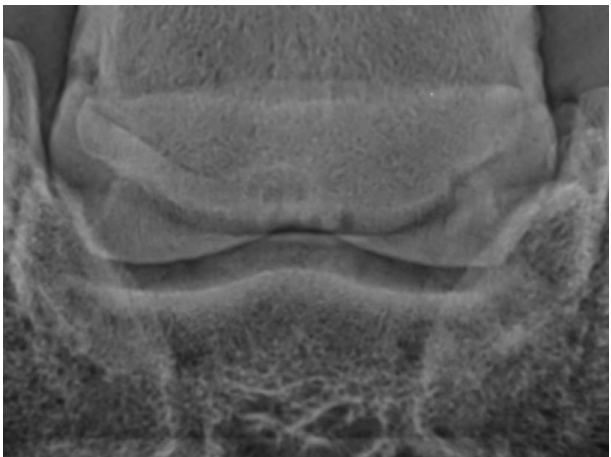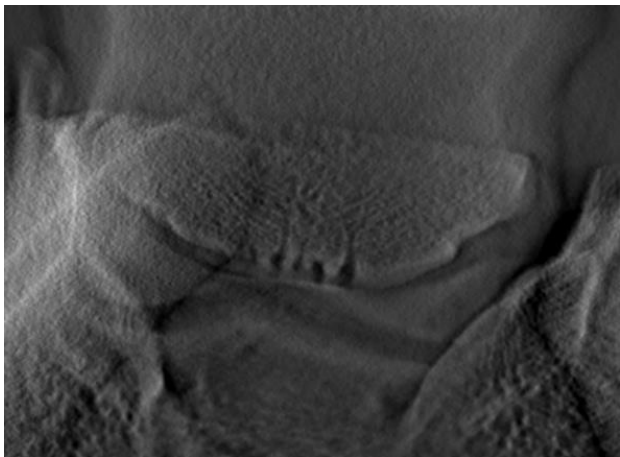
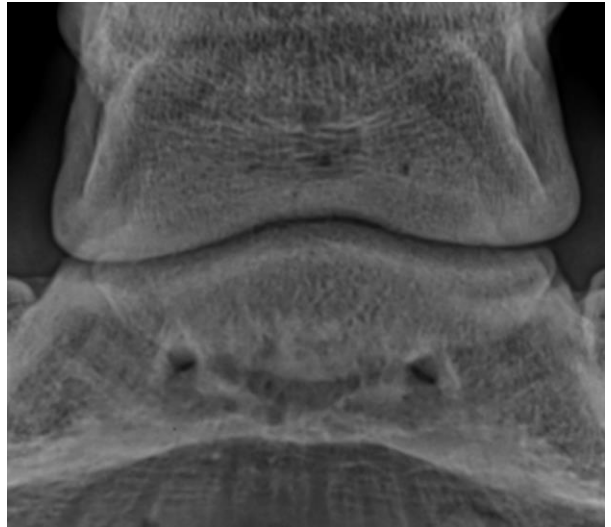
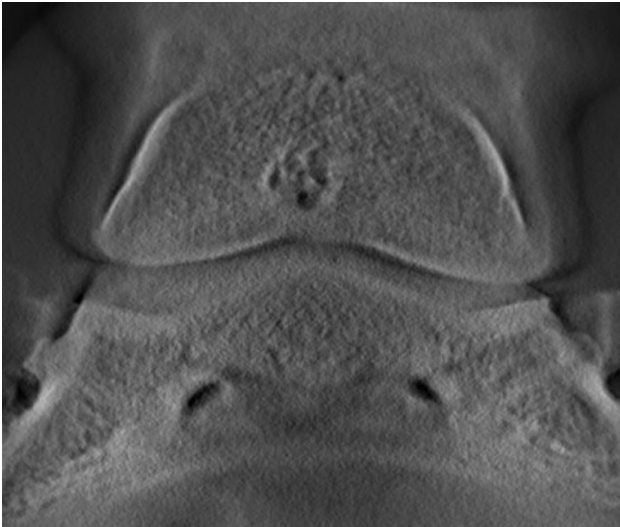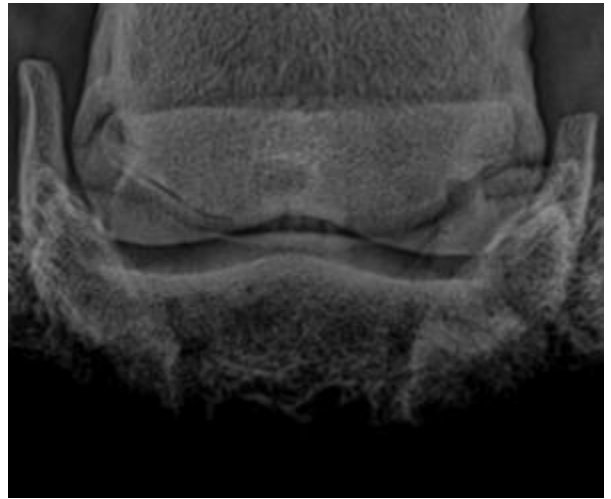
RAD



DTS



RAD



Diagnosis: subchondral bone cyst of middle phalanx.