

## EQUINE TOMOSYNTHESIS

Teeth (A0028, 26 Mar 2020)

Gelding 10 years old, riding horse. During routine dental examination abnormalities of the mandibular tooth 309 were observed. The left mandibular ramus was thicker than right one in the chick region and there was an unpleasant odor from the oral cavity. Decided to do an x-ray and tomosynthesis examination.

There is visualized first molar tooth fracture with the formation of several fragments and periapical lysis with dystrophic mineralization around tooth root (Fig 1,2).




Figure 1. Tomosynthesis slice lateral view of the left ramus of the mandible.

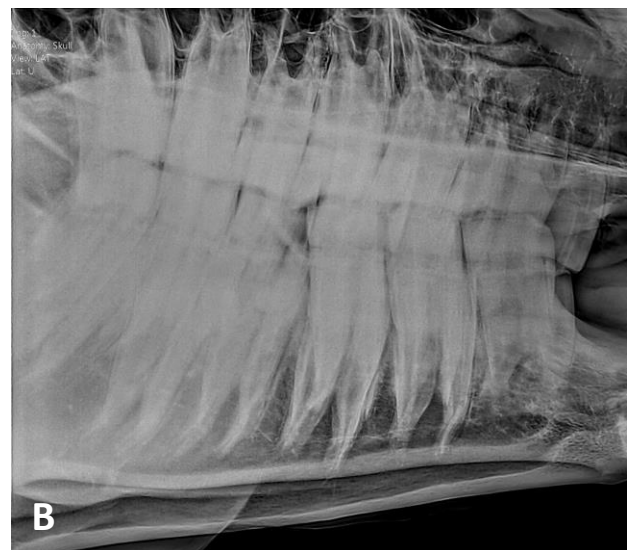
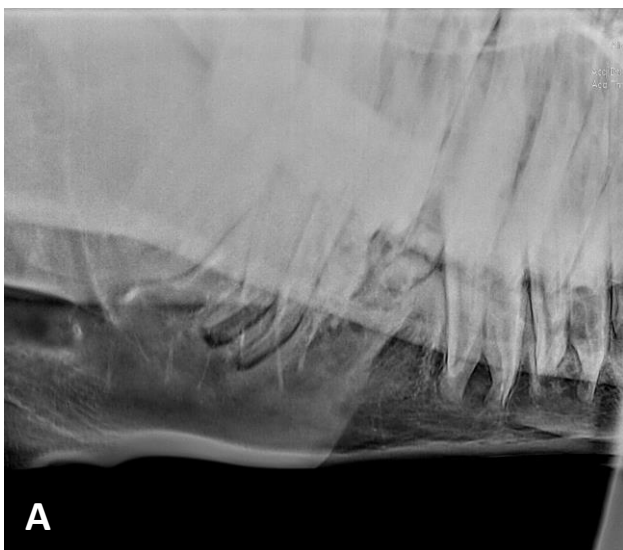

Fig 2. DR x-ray of the left oblique (A) and slightly oblique lateral (B) views of the mandible.

**Diagnosis:** 309 tooth fracture with chronic infectious process.