

EQUINE TOMOSYNTHESIS

Pastern (S0034, 16 May 2019)

2 years old thoroughbred racehorse stallion, suddenly severe lame in the right front while training. Multiple fracture lines in P1 visible in normal x-rays (DR). Referred to clinic for surgery.

Pre surgery tomosynthesis scans in different angles were performed for planning screw-positioning because of helical orientation through the bone. In proximal P1 wide fracture line starting at the sagittal ridge at the level of the fetlock joint, more distally departing into two main lines with a fragment in between, the medial one bit thinner than the lateral one which is turning direction from sagittal into the frontal plane and is ending in the pastern joint.

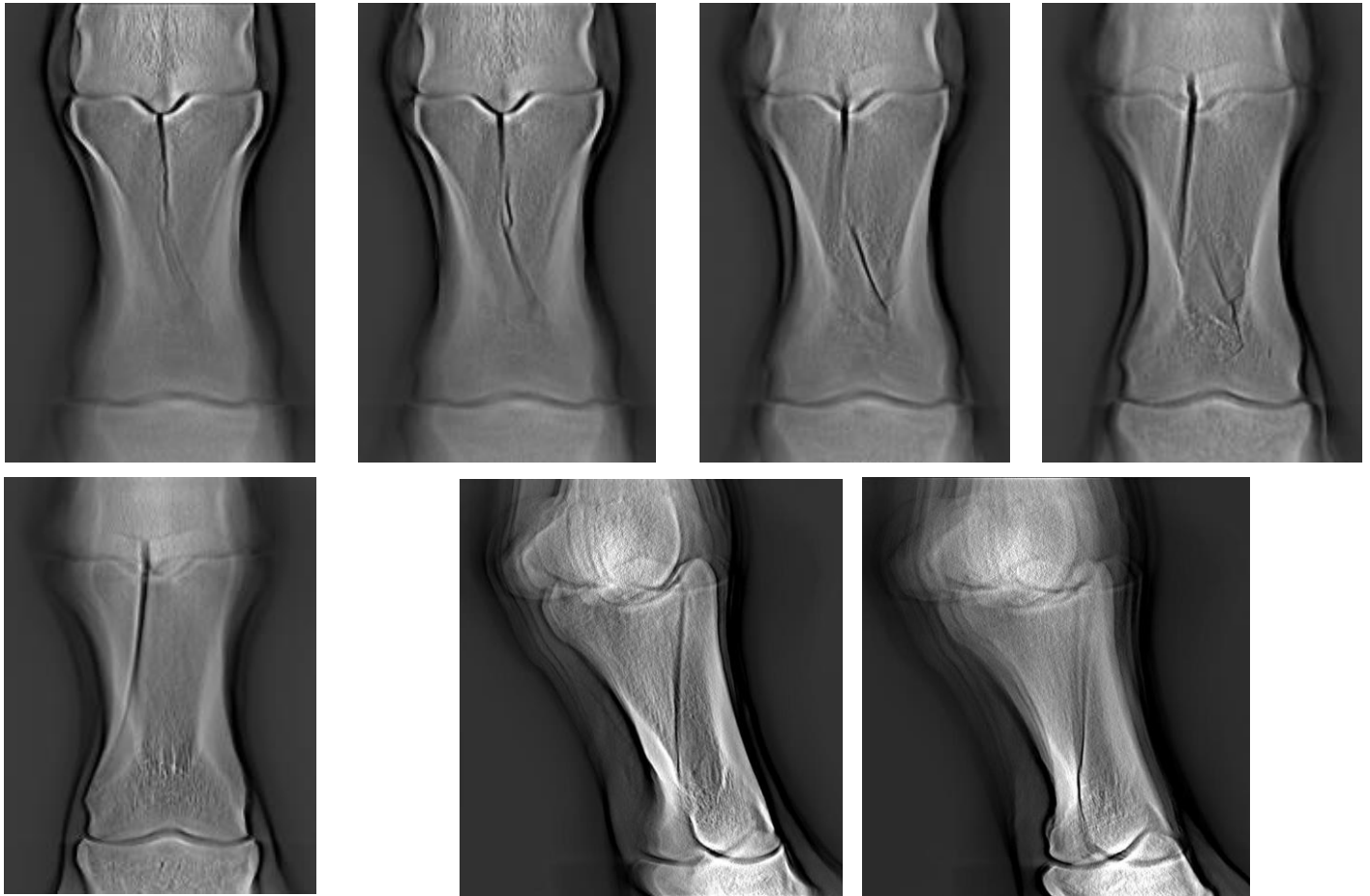


Fig 1. Tomosynthesis dorso-palmar and oblique view slices of P1 fracture.

Diagnosis: Proximal P1 fracture.