

EQUINE TOMOSYNTHESIS

Hock (C0033, 22 Jul 2019)

Six years old Andalusian stallion, with acute left hock soft tissue swelling and moderate tarsocrural joint effusion after an accidental fall occurred two weeks ago. There is a mild LH lameness and hock flexion is positive.

Left hock radiographs reveal a subtle radiolucent oblique line localized on the dorso-proximal region of the third tarsal bone.

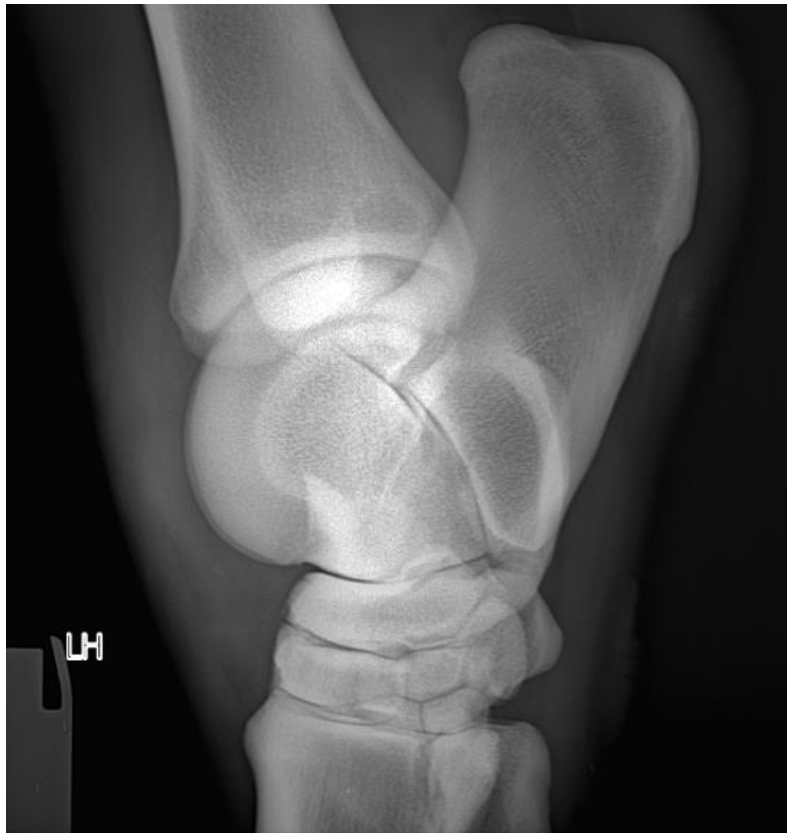


Fig 1. DR x-ray lateromedial view image.

Tomosynthesis study confirms the presence of an articular fracture minimally displaced of the third tarsal bone. The horse responded favorably to conservative treatment (rest) and is actually working with normality.

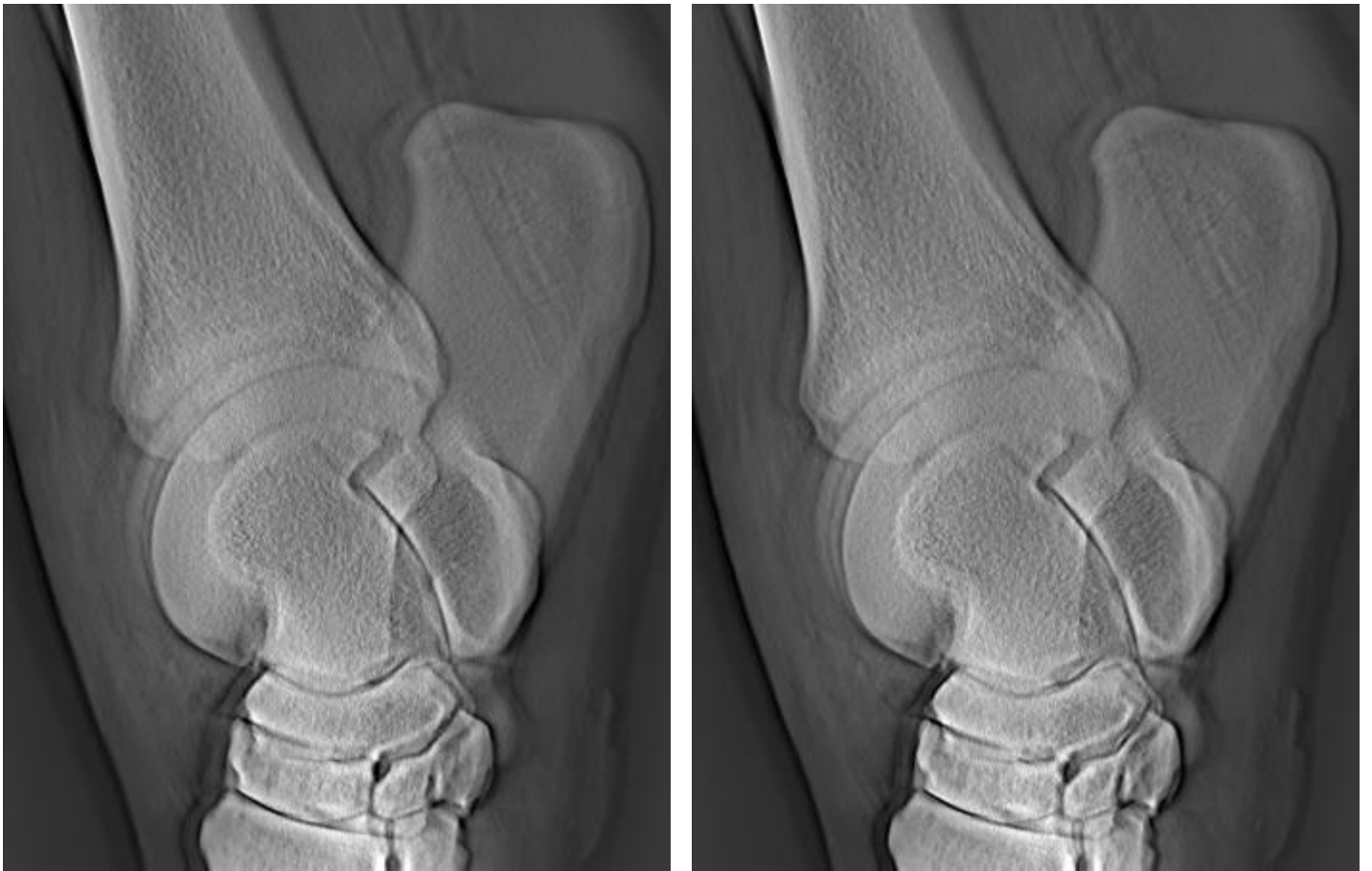

Fig 2. Tomosynthesis lateromedial view slices (with 3mm distance between them).

Diagnosis: Incomplete articular fracture of the third tarsal bone of the left hind limb.