

## EQUINE TOMOSYNTHESIS

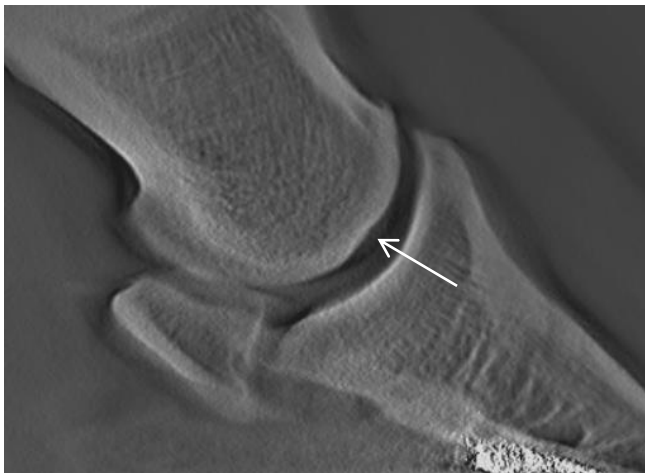
RF Foot (L0020, 10 Sep 2019)

Jumping mare 10 years old. Lameness both front feet on hard ground on small circle. Synovitis of the right front fetlock joint, dynamic flex test positive (degree 3 from 4). Synovitis of the right tarsal joint, dynamic flex test was negative. EqueTom and DR x-ray images were made for comparative evaluation of findings.

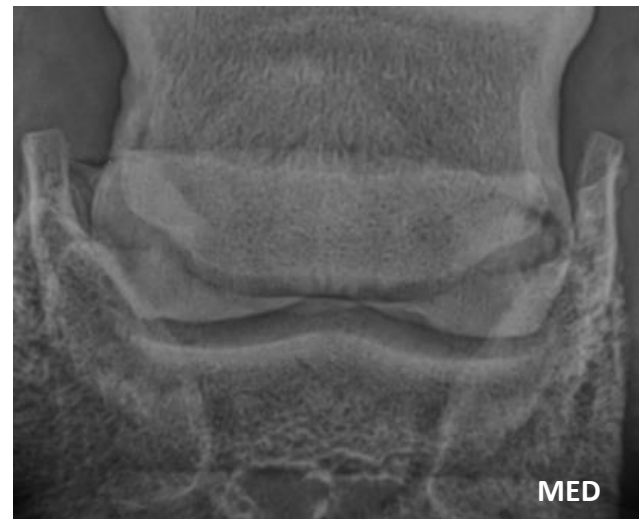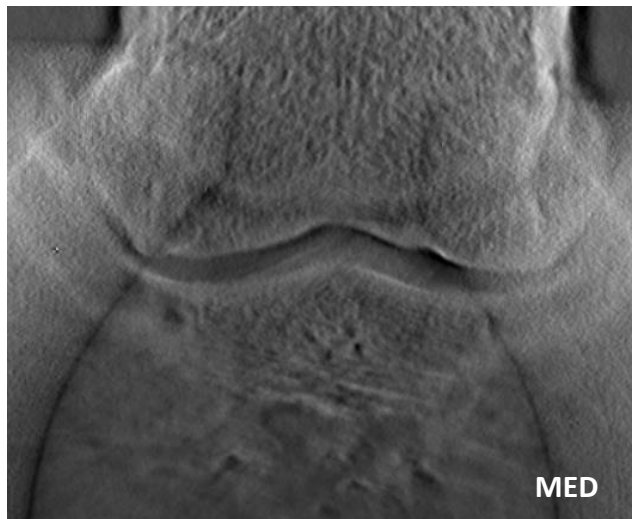
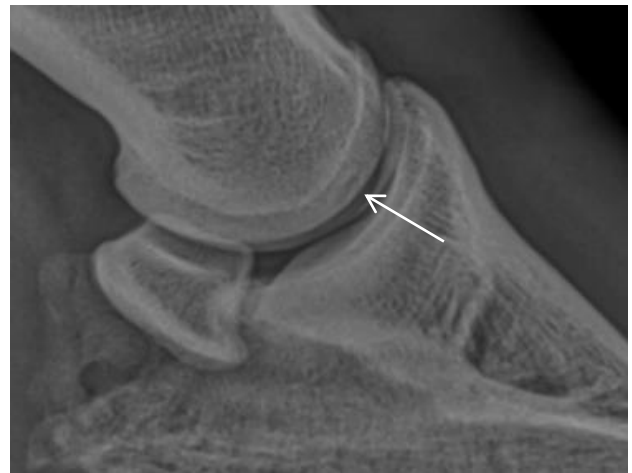
### RF Foot

There is irregular articular surface and small subchondral lateral and medial condyles defect of the middle phalanx.

DTS



RAD



**Diagnosis:** osteochondrotic lesions of middle phalanx.