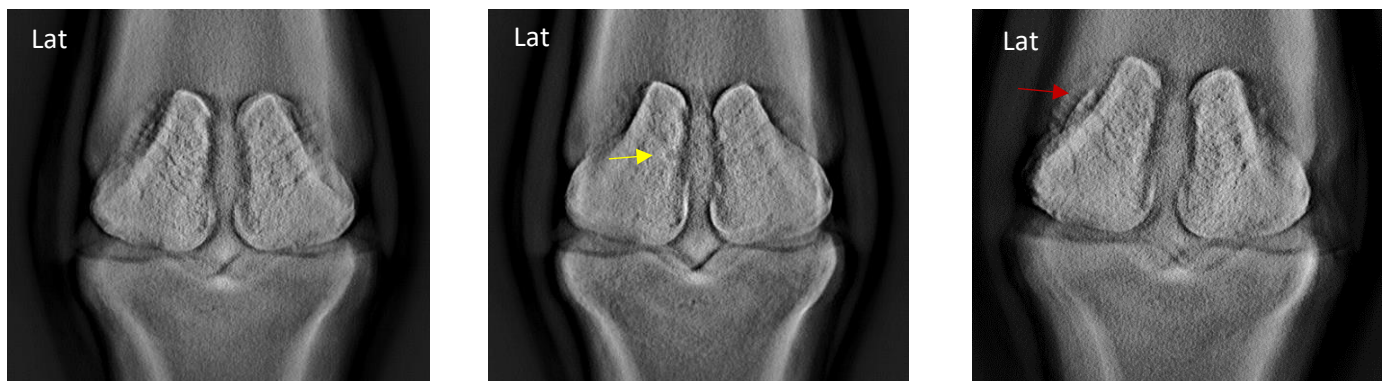


EQUINE TOMOSYNTHESIS

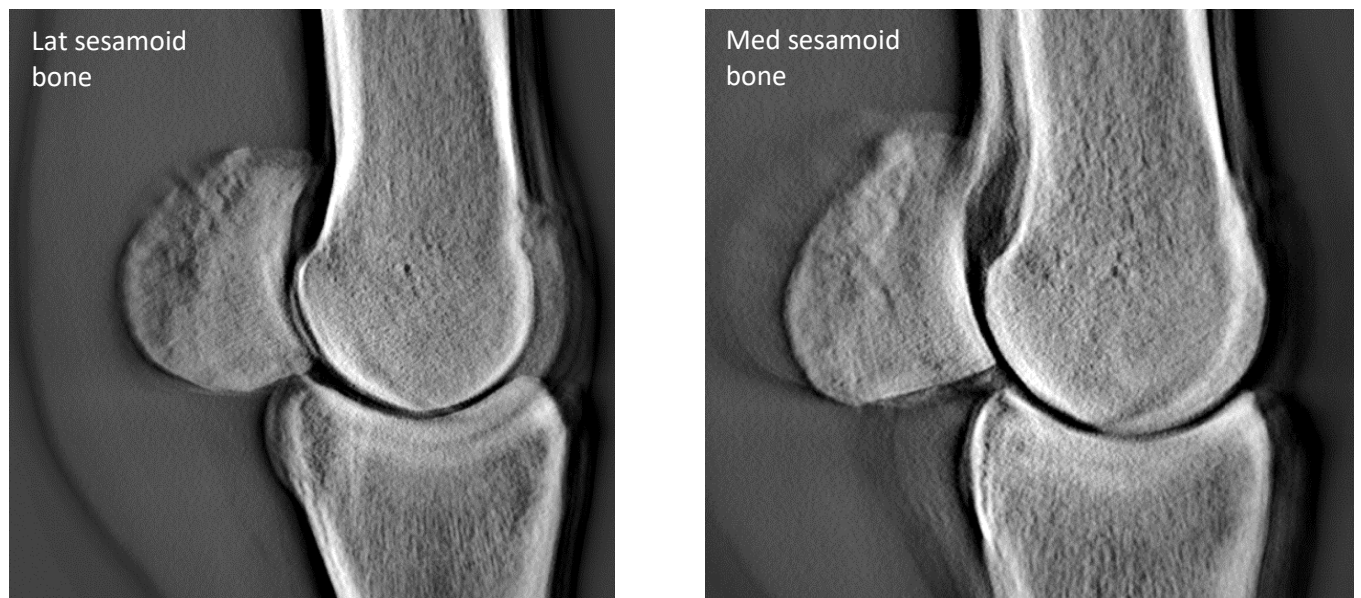Fetlock (C0025, 18 Dec 2019)

Mare 4 years old, jumping discipline. The horse displayed severe lameness of right front leg; it cannot be related to this leg (grade 5 out of 5). Swelling of the fetlock joint region, especially palmar aspect with slight edema of digital flexor tendon sheath.

On dorsopalmar (DP) view observed moderate amount of symmetrical osteolysis affecting apical to mid-body axial margins of the medial and lateral proximal sesamoid bones. There is a small cystic lesion in the axial margin of the mid-portion of the lateral proximal sesamoid bone (yellow arrow). Small calcification fragment abaxial apical margin of the lateral proximal sesamoid bone (red arrow).



On lateromedial (LM) view observed the loss bone radiopacity and not well defined margins of the proximal and mid-portion palmar aspects of the lateral and medial proximal sesamoid bones.



Diagnosis: Osteitis of the proximal sesamoid bones, possible as the infection result.