

EQUINE TOMOSYNTHESIS

Pastern (D0026, 16 Jan 2020)

Mare 11 year old, jumping. Presented for evaluation of right forelimb lameness. Sound following distal palmar digital nerve block, but not improve after coffin joint block.

Dorsopalmar (DP) view of the pastern, showing two sagittal lucent lines extending from articular surface of the medial condyle 2nd phalanx at the palmar cortices' slices in focus (Fig 1). These changes not visualized closer to the dorsal cortices of 2nd phalanx (Fig 2).

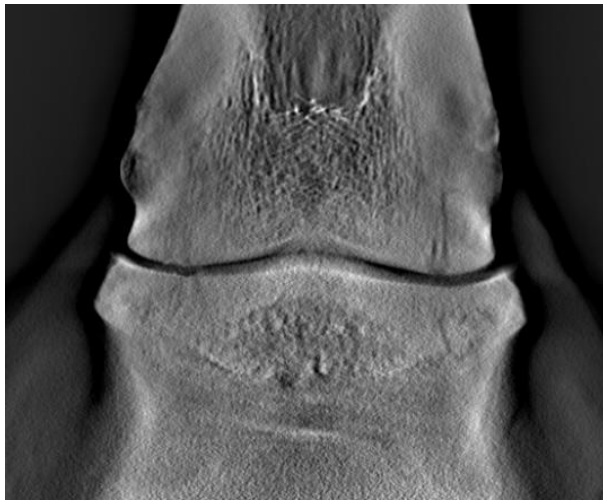

Fig 1. DTS slice #140

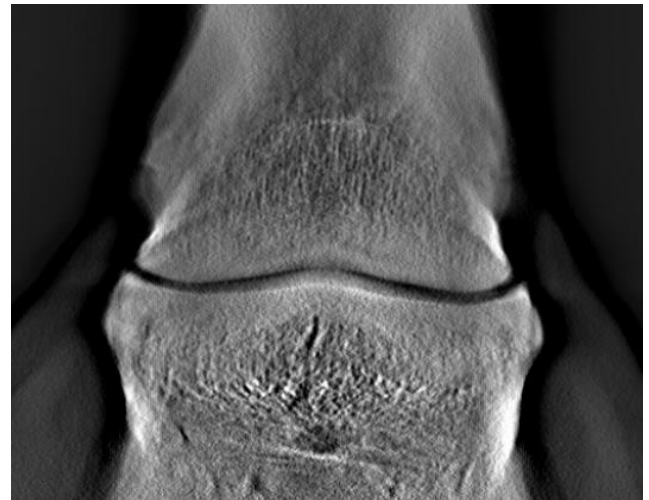


Fig 2. DTS slice #160

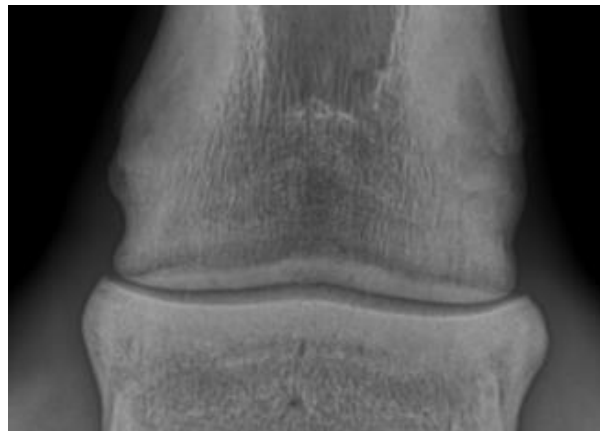


Fig 3. DR image

Diagnosis: Crack of the medial condyle of 2nd phalanx.