

EQUINE TOMOSYNTHESIS

Sinus (D0037, 10 May 2020)

Short description: Yearling with a sinus abscess.

Zangersheide yearling, stertorous breathing on pasture, general conditions good. The day after this breathing noise increased and a swelling under the right eye was detected. Brought to clinic with suspicion of an abscess.

Temperature 38.5°, auscultation lungs okay but trachea with a loud stridor nasalis. Left nostril stridor of high degree, right nostril no breathing possible.

Hard swelling under right eye of 3x3cm size, not painful. Right mandibular lymph node enlarged but not painful.

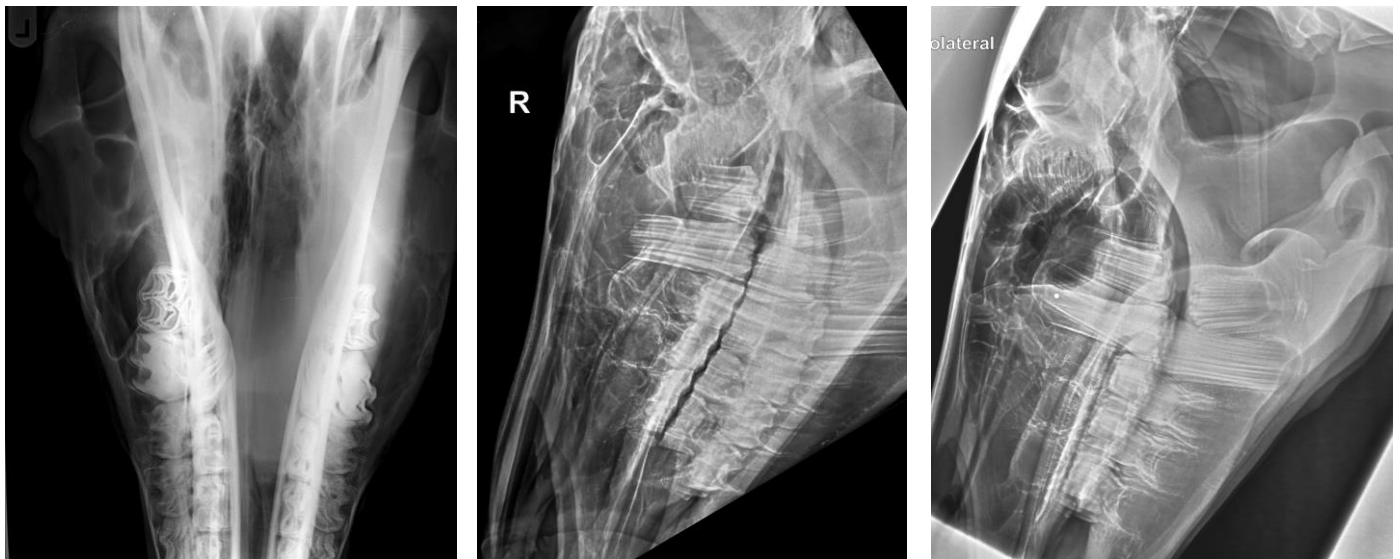


Fig 1. X-ray images.

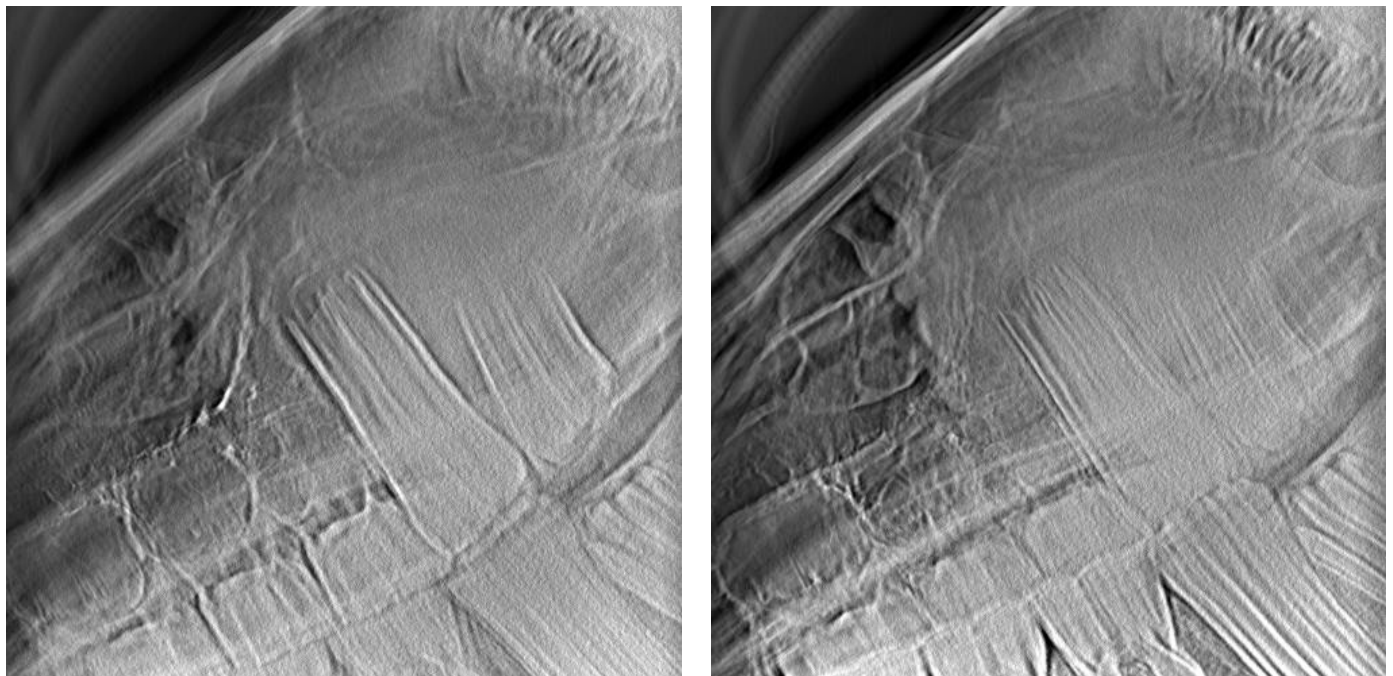


Fig 2. Tomosynthesis slices.

Endoscopy: Exudate in nasal passage, not stinking. Pronounced follicular hyperplasia, enlarged lymph node in the right Diverticulum tubae auditivae. Both diverticulae without purulence. Horse starts getting a DDSP during endoscopic examination.

X-ray & EQUETOM: More dense region in the right sinus; soft tissue swelling on the right maxilla in AP-view (just x-ray); teeth without any finding.

Blood: Leucocytosis, neutrophilia and monocytose.

Treatment: Surgical trepanation of the right caudal sinus maxillaris opened a purulent abscess.

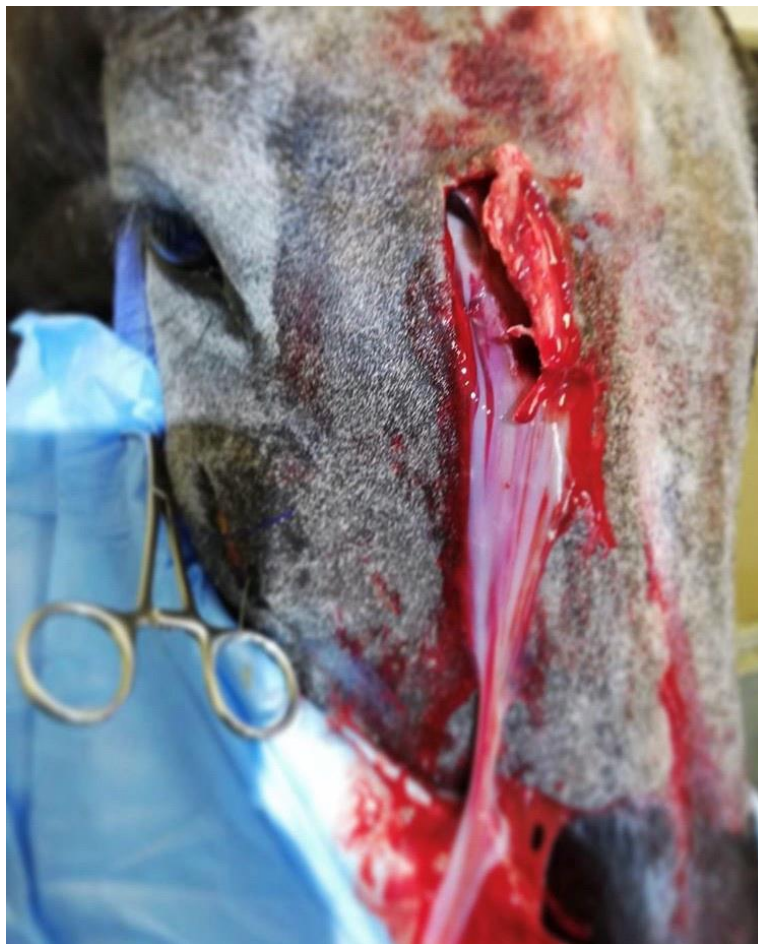

Fig 3. Surgical trepanation of the right caudal sinus maxillaris